

Delivery through a Cervical Tear in a Patient with a History of Loop Electrosurgical Excision Procedure and Intact Cervical Os

Viola YT CHAN MBBS

Wai-Lam LAU MBBS, FRCOG, FHKAM (O&G)

Wing-Cheong LEUNG MD, FRCOG, FHKAM (O&G), Cert RCOG (Maternal & Fetal Med)

Department of Obstetrics and Gynaecology, Kwong Wah Hospital, 25 Waterloo Road, Hong Kong

Vaginal delivery through a cervical tear with an intact cervical os is rare. A para one, 35-year-old pregnant woman was admitted for induction of labour at 41 weeks of gestation. She had a history of cervical intraepithelial neoplasia treated with a loop electrosurgical excision procedure 4 years after her first pregnancy. Three doses of vaginal prostaglandin E2 were given for cervical priming. She went into labour 5 hours after the third dose of prostaglandin E2. No syntocinon infusion was administered. After successful delivery of the baby, she had severe vaginal bleeding. Thorough examination in the operating theatre revealed a cervical tear at 3 o'clock, with an intact cervical os of around 5 mm. The cervical tear was repaired. Total blood loss was 700 ml. The patient underwent an uneventful postoperative course and was discharged 4 days later. We conclude that special attention should be paid to women with a history of cervical procedure. If there is evidence of cervical stenosis during spontaneous or induced labour, Caesarean section needs to be considered to prevent complications. Such complications include cervical effacement without corresponding cervical dilatation in the presence of good regular uterine contractions.

Hong Kong J Gynaecol Obstet Midwifery 2012; 12:86-8

Keywords: Cervical intraepithelial neoplasia; Electrosurgery; Laser therapy; Obstetric labor; Pregnancy complications, neoplastic

Introduction

Cervical intraepithelial neoplasia (CIN) is commonly diagnosed in women of reproductive age. The incidence of cervical cancer in women aged 20 to 50 years in Hong Kong is 0.8 to 16.5 per 100 000¹. With the introduction of population screening, more women of reproductive age have been diagnosed with CIN. Its treatment options include ablative procedures such as cold-

knife conisation, loop electrosurgical excision procedure (LEEP), and laser conisation. Previous studies have shown that LEEP is associated with an increased risk of preterm delivery, preterm premature rupture of membranes, and low-birth-weight infants in subsequent pregnancies^{2,3}. We report a case of delivery through a cervical tear with an intact cervical os in a patient with a history of LEEP and a scarred cervix.

Table. Characteristics of cases

	Age, parity, gestation	Medical history	Cervical status at initial assessment	Induction of labour
Oyelese et al ⁵ , 2001	33 years old, para 0 ⁺¹ , 38 weeks	Not mentioned	Long and closed, station-4	25 µg vaginal misoprostol, every 3 hours x 4
Uchil et al ⁴ , 2006	38 years old, para 0 ⁺¹ , 38 weeks	Not mentioned	5 cm dilated	No
Present case	35 years old, para 1, 41 weeks	Normal vaginal delivery in 2004; CIN with LEEP 1 year before index delivery	Long and closed, modified Bishop score of 3/13	1.5 mg PGE2 x 3, artificial rupture of membranes for augmentation, no syntocinon given

Abbreviations: CIN = cervical intraepithelial neoplasia; LEEP = loop electrosurgical excision procedure; PGE2 = prostaglandin E2

Correspondence to: Dr. Viola YT Chan

Email: cyt141@ha.org.hk

Case Report

The patient, a Chinese woman aged 35 years, was in her fifth pregnancy. She had had three terminations of pregnancy in 1998, 2000 and 2001, followed by a spontaneous vaginal delivery in Mainland China in 2004, at which time she delivered a boy weighing 3.35 kg. She underwent manual removal of placenta, but did not recall any other complications such as severe blood loss or any genital tear. We traced but could not retrieve the details of her delivery in the Mainland.

She had a history of CIN II treated in China with LEEP in June 2008. No record of the procedure was available for review. There was no symptom to suggest cervical stenosis as her menses were normal after the procedure and the current pregnancy was spontaneously conceived. During the booking visit at 23 weeks of gestation, speculum examination did not reveal any abnormalities. She was diagnosed to have impaired glucose tolerance (oral glucose tolerance test, 4.9/8.2), for which she did not receive a special diabetic diet (according to our unit protocol). Her antenatal course was otherwise uneventful.

She was admitted at 41 weeks of gestation for induction of labour owing to a post-date pregnancy. Cervical assessment on admission revealed a posterior pointing cervix of medium consistency with a closed 1 cm thick os, vertex presentation, station S-2 (Modified Bishop Score 3/13). In view of the unfavourable cervix, two doses of prostaglandin E2 (PGE2) 1.5 mg each were given vaginally 24 hours apart for cervical ripening. Cervical assessment after two doses of PGE2 revealed a soft cervix, with the os being just a dimple (~0.5 cm dilated), 1 cm in length. Scarring was suspected owing to the history

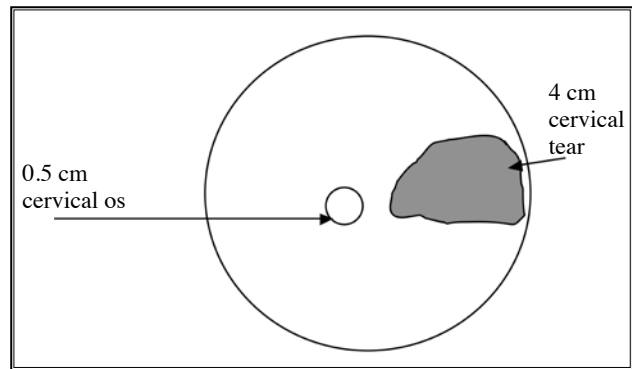


Figure. Baby's head delivered through cervical tear

of LEEP. Difficulty in artificial rupture of membranes was anticipated. As our patient was very keen on vaginal delivery, artificial rupture of membranes was attempted but failed. After due discussion with the patient, a third dose of 1.5 mg PGE2 was given to further ripen the cervix. Our patient went into spontaneous labour 5 hours later. Vaginal examination indicated that the cervical os remained 0.5 cm dilated but was fully effaced and soft. Artificial rupture of membranes was performed successfully. No syntocinon infusion was given in view of the frequent contractions (three in 10 minutes). A baby girl weighing 4.06 kg was born by normal vaginal delivery 2 hours later. The patient had severe vaginal bleeding after delivery of the placenta; bedside examination showed an extensive cervical tear at 3 o'clock with a large amount of bleeding. Thorough examination under anaesthesia in the operating theatre showed a cervical tear at 3 o'clock, 4 cm deep, with no extension to the uterus / fornix (Figure). The original cervical os remained 0.5 cm dilated on examination. As the apex of the cervical tear was clearly identified and the ultrasound confirmed no free fluid in the pouch of Douglas, it was evident that the tear did not extend to the uterus /

Progress of labour	Mode of delivery	Type of cervical injury	Outcome
Good, cervix fully dilated at 15 hours after initial dose of misoprostol	Spontaneous vaginal delivery	Extensive midline tear at posterior lip of cervix, up to cul-de-sac	Female baby of 6 lb 8 oz; tear was repaired, total blood loss 800 cc
Good	Spontaneous vaginal delivery	Internal os was only 3-4 cm dilated but with a large posterior tear 2.5 cm from the os and extending to the posterior fornix but without a colporrhexis	No mentioning of baby's birth weight and sex; examination under anaesthesia and repair of tear by consultant obstetrician
Delivery 2 hours after artificial rupture of membranes (5 hours after last dose of PGE2)	Spontaneous vaginal delivery	Internal os was only 0.5 cm dilated but with a 4-cm lateral cervical tear with no extension to uterus / fornix	Female baby of 4.06 kg; examination under anaesthesia and repair of tear by consultant obstetrician

fornix. The cervical tear was repaired with continuous sutures with vicryl. Normal drainage through cervical os was confirmed at the end of the operation with successful insertion of the tip of a pair of packing forceps. Total estimated blood loss was 700 ml, which could have been an underestimate, as the haemoglobin level dropped from 111 g/L before delivery to 79 g/L thereafter. The patient received iron supplements, underwent an uneventful postoperative course, and was discharged on day 4 postpartum. In view of the scarred cervix which failed to dilate during labour, for future pregnancies she was advised to have elective lower segment Caesarean section before the onset of labour.

Discussion

Delivery through a cervical tear with an intact cervical os is rare. One case of spontaneous vaginal delivery through an unusual posterior cervical tear was reported by Uchil et al⁴ in 2006. Another case was reported by Oyelese et al⁵ in 2001, in which an extensive posterior cervical tear was found after four doses of misoprostol given for induction (Table^{4,5}). Both cases may not really be comparable to ours in whom cervical stenosis was demonstrated. As the cervixes were either fully dilated or 5 cm dilated in these two cases, one may regard them as co-existing large cervical tears rather than genuine delivery through a cervical tear. Cervical tear after misoprostol was more often reported in midtrimester abortions⁶. There were no reports of cervical tear with a scarred cervix and induction of labour.

The local LEEP involves complete excision of the transformation zone with a diathermy loop. The scarred tissue on the cervix decreases in structural integrity and thus the ability to carry a pregnancy to term. On the other hand, the scarred tissue can cause narrowing of the cervical os, the extreme situation being cervical stenosis⁷, defined by an inability to introduce a 1- to 2-mm dilator into the uterine cavity. The reported incidence of cervical stenosis

after LEEP varies between 0 and 26%. In our patient, the scarred cervix caused substantial stenosis, as the cervical os remained as a dimple and did not dilate despite adequate uterine contractions. With softened cervical tissue after cervical priming, and the presence of good uterine contractions, the cervical tissue was weakened and gave way to allow delivery of the baby through the torn cervical canal. As the cervix would clamp down after delivery, the actual tear might have been greater than 4 cm in length. Retrospectively, the tight cervical os before artificial rupture of membranes was perhaps already a sign of proneness to failed induction of labour. Cervical priming by the laminaria tent has been successfully used and proved to be safe in refractory cases of cervical stenosis before embryo transfer⁸. In this scenario, it should be considered as an alternative. Delivery through a cervical tear with an intact cervical os might have been prevented if Caesarean section was chosen in view of the unfavourable cervical status even after repeated PGE₂ for cervical ripening.

This case illustrates how patients of reproductive age with CIN should be counselled before carrying out the excisional procedure. Women should be informed of the confirmed association between LEEP and preterm delivery, preterm premature rupture of membranes and low-birth-weight infants^{2,3}. Vaginal delivery is not contraindicated for women with a history of an excisional procedure on the cervix. There is no evidence for recommending routine Caesarean section, even if cervical stenosis is suspected. Trial of labour can be attempted. A truly stenotic cervix would normally fail to dilate during labour and Caesarean section could be performed if there was no progress. However, if there is evidence of cervical effacement without corresponding cervical dilatation in the presence of good regular uterine contractions, Caesarean section needs to be considered immediately to prevent complications, such as that occurred in our case.

References

1. Hong Kong Cancer Registry website: www3.ha.org.hk/cancereg/e_stat.asp. Hong Kong: Department of Health. Accessed October 2011.
2. Arbyn, M, Kyrgiou M, Simoons C, et al. Perinatal mortality and other severe adverse pregnancy outcomes associated with treatment of cervical intraepithelial neoplasia: meta-analysis. *BMJ* 2008; 337:a1284.
3. Sadler L, Saftlas A, Wang W, et al. Treatment for cervical intraepithelial neoplasia and risk of preterm delivery. *JAMA* 2004; 291:2100-6.
4. Uchil D, Kumakech W, Jolaoso A. Spontaneous vaginal delivery through an unusual posterior cervical tear. *J Obstet Gynaecol* 2006; 26:263-4.
5. Oyelese Y, Landy HJ, Collea JV. Cervical laceration associated with misoprostol induction. *Int J Gynaecol Obstet* 2001; 73:161-2.
6. El-Etriby EK, Daw E. Rupture of the cervix during prostaglandin termination of pregnancy. *Postgrad Med J* 1981; 57:265-6.
7. Baldauf JJ, Dreyfus M, Ritter J, et al. Risk of cervical stenosis after large loop excision or laser conization. *Obstet Gynecol* 1996; 88:933-8.
8. Glatstein IZ, Pang SC, McShane PM. Successful pregnancies with the use of laminaria tents before embryo transfer for refractory cervical stenosis. *Fertil Steril* 1997; 67:1172-4.