

Sentinel lymph node mapping in endometrial cancer: an updated review

Jacqueline HS LEE¹, MBChB, MRCOG, MHKCOG, FHKCOG, FHKAM(O&G), MSc in Medical Genetics(CUHK)
Joshua JX LI², MBChB, PDip Epidemiology and Biostatistics (CUHK), PGDipClinDerm(QMUL), FHKCPath, FHKAM (Pathology)

¹ Department of Obstetrics and Gynaecology, Faculty of Medicine, The Chinese University of Hong Kong

² Department of Anatomical and Cellular Pathology, Faculty of Medicine, The Chinese University of Hong Kong

Sentinel lymph node mapping (SLNM) is widely used in staging of both low- and high-risk early-stage endometrial cancer. It has a high detection rate, high sensitivity, high negative predictive value, and low false negative rate in detection of lymph node metastasis. Cervical injection of indocyanine green for SLNM is the preferred method. SLNM reduces the number of lymph node removal and reduces complications from lymphadenectomy without compromising oncological safety. This review discusses the latest evidence of SLNM in endometrial cancer staging in terms of technique, accuracy, limitations, impact on lymphadenectomy complications, and cancer survival.

Keywords: Endometrial neoplasms; Lymph node excision; Neoplasm staging; Sentinel lymph node

Introduction

Endometrial cancer is the commonest gynaecological malignancy in the developed world, with the incidence increasing rapidly. It is the 4th commonest female cancer in the USA, with a 1% increase in incidence every year¹. In Hong Kong, a similar trend is observed. According to the Hong Kong Cancer Registry, the incidence increased from 15/100 000 in 2015 to 17/100 000 in 2019². Lymphadenectomy has been an integral part in the management of endometrial cancer since the use of surgical staging³ and the incorporation of positive lymph nodes as stage IIIC in the International Federation of Gynecology and Obstetrics staging⁴. Chemotherapy and/or radiotherapy improves the 5-year overall survival (OS) of stage IIIC endometrial cancer from 69.8% to 78.7%^{5,6}. Thus, accurate assessment of lymph node involvement is crucial for the optimal management of endometrial cancer, especially in high-risk endometrial cancer, which has a 10% chance of lymph node metastasis⁷. However, complete pelvic and para-aortic lymphadenectomy lacks a therapeutic effect and is associated with morbidities such as lymphedema. Sentinel lymph node mapping (SLNM) may decrease morbidity without compromising survival. It is widely used in the management of early-stage low-risk (well-differentiated or moderately differentiated, grade 1-2, <50% myometrial invasion, <2 cm tumour) endometrial cancer⁸. It also achieves similar oncological safety and accuracy in early-stage high-risk (grade 3 endometrioid histology, non-endometrioid histology, deep myometrial invasion, cervical invasion, and presence

of lymphovascular space invasion) endometrial cancer. 82% of US gynaecology oncology surgeons⁹ and 50% of gynaecology oncology surgeons among 69 countries self-report to use SLNM when managing endometrial cancer¹⁰.

Controversies on lymphadenectomy

The standard treatment of endometrial cancer is total hysterectomy + bilateral salpingoophorectomy +/- pelvic lymphadenectomy +/- para-aortic lymphadenectomy. However, the role and extent of complete pelvic and para-aortic lymphadenectomy remain controversial. Some studies reported therapeutic benefits from lymphadenectomy¹¹⁻¹³. Others reported that lymphadenectomy provided no additional therapeutic benefit for early-stage endometrial cancer, with similar progression-free survival (PFS) and OS between those with or without lymphadenectomy^{14,15}, but the proportion of low-risk patients was larger and the adjuvant therapy was not standardised in the two studies. The risk of lymph node involvement is only 1% to 2%^{7,16} for early-stage low-risk endometrial cancer. In a retrospective study of 268 low-risk endometrial cancer patients, 2.4% had lymph node metastasis. Although the risk of lymph node metastasis is 11.4% for high-risk endometrial cancer patients, 88.6% of patients will still receive unnecessary lymphadenectomy and thus had morbidities such as

Correspondence to: Ho Sze Jacqueline LEE

Email: jaclee@cuhk.edu.hk

lymphedema⁷. Given the lack of therapeutic benefit, low risk of lymph node metastasis, and morbidity, the role of complete lymphadenectomy is questionable in low-risk endometrial cancer. Some centres advocate complete pelvic +/- para-aortic lymphadenectomy for all patients¹³, whereas others advocate lymphadenectomy for high-risk endometrial cancers only^{12,17}. The strategy of Mayo Clinic is to omit complete lymphadenectomy in low-risk endometrial cancers⁸. However, upstaging of disease on final histology is not uncommon, only 47% of presumed stage 1A, grade 1 disease remain so on final histology¹⁸. Neither preoperative clinical risk factors nor imaging is accurate in predicting metastasis to lymph nodes. Magnetic resonance imaging, positron emission tomography computed tomography, and positron emission tomography magnetic resonance imaging have a low sensitivity of 60% to 70%¹⁹.

Sentinel lymph node mapping

Sentinel lymph node refers to the first lymph node that receives lymphatic drainage from the primary malignant tumour. SLNM is based on the presumption that lymphatic drainage occurs stepwise from the most proximal lymph node to the tumour site to more distal lymph nodes. Theoretically, SLN is the first to metastasise in a regional lymphatic drainage area. With a negative SLN, the whole lymphatic drainage area is considered negative for metastasis. SLNM involves selective removal of lymph nodes at highest risk of metastasis as identified by tracers injected near the primary malignant tumour. The detection rate, bilateral detection rate, sensitivity, negative predictive value (NPV), and false negative rate of SLNM are key parameters for its performance. Detection rate is the percentage of patients with at least one SLN being detected. Bilateral detection rate refers to the percentage of patients with SLN being detected at bilateral pelvis. Sensitivity is defined as the proportion of positive SLN to the total number of patients with lymph node metastasis. NPV is defined as the percentage of patients with negative SLN to the total number of patients with negative non-SLN. False negative rate is defined as the percentage of patients with negative SLN but positive non-SLN. SLNM is the standard of practice in breast cancer, vulval cancer, and melanoma. SLNM was first reported in 1996 in 15 endometrial cancer patients²⁰. The SENTICO-ENDO study in 2011 showed a promising result, with a sensitivity of 84% and NPV of 97%²¹.

What tracer to inject?

Technetium-99m (Tc-99m), blue dye (isosulfan blue, methylene blue), indocyanine green (ICG), and combinations of tracers have been used to locate the SLN.

ICG is the most recommended tracer, owing to its high detection rate, consistency, and ease of administration.

Radiolabelled Tc-99m can drain through lymph nodes and emit gamma rays that can be detected by preoperative nuclear imaging and intraoperative gamma counters. Tc-99m is usually injected 1 day before surgery for preoperative lymphoscintigraphy, which can be fused with single-photon emission computed tomography for greater precision²². A collaboration with a nuclear medicine unit is required. Injection of tracer is painful to the patient. The required injection dose is calculated based on the estimated time interval to the surgery; this limits flexibility should the surgery be advanced or deferred and requires meticulous preoperative planning. Thus, the use of intraoperative gamma counters only is proposed²². However, radio-injury to surgeons and patients and the lack of equipment remain potential problems^{17,23}. The detection rate of Tc-99m is lower than that of ICG (53.3% vs 73.8%)²⁴. Tc-99m is often used with the colorimetric method to increase the detection rate. The gamma counters can identify areas of hot signals, and coloured dye can guide the dissection. ICG is superior to combined blue dye and Tc-99m, with higher SLN detection rate (100% vs 96%) and bilateral mapping rate (98.5% vs 76.3%)²⁵. The COMBITEC study concluded that there is no benefit to add Tc-99m to ICG, owing to increased procedure time and no difference in the SLN detection rate²⁶.

Colorimetric lymphatic mapping involves visual detection of lymphatic channels with coloured dye in white light¹⁷. Isosulfan blue is costly and associated with a risk of potentially life-threatening allergic reactions²⁷. Approximately 1% to 2% of patients experience allergic reactions with isosulfan blue. Methylene blue is less expensive and associated with much less allergic reactions²⁷. However, SLNM with methylene blue is an off-label use. It carries a risk of paradoxical methemoglobinemia and serotonin syndrome in patients taking serotonergic psychiatric medications¹⁷. Breast cancer studies showed a similar SLN detection rate for isosulfan blue and methylene blue²⁷. Injection of methylene blue and ICG to each side of the cervix in the same patient showed a higher SLN detection rate with ICG than with methylene blue (90.9% vs 64.4%)²⁸. The use of ICG increases the SLN detection rate per hemi-pelvis by 26.5%²⁸.

ICG emits fluorescent signal in near-infrared light range (830 nm wavelength). An equipment for near-infrared light range imaging is required to identify the SLN (Figure). The risk of adverse event is extremely low (0.07%

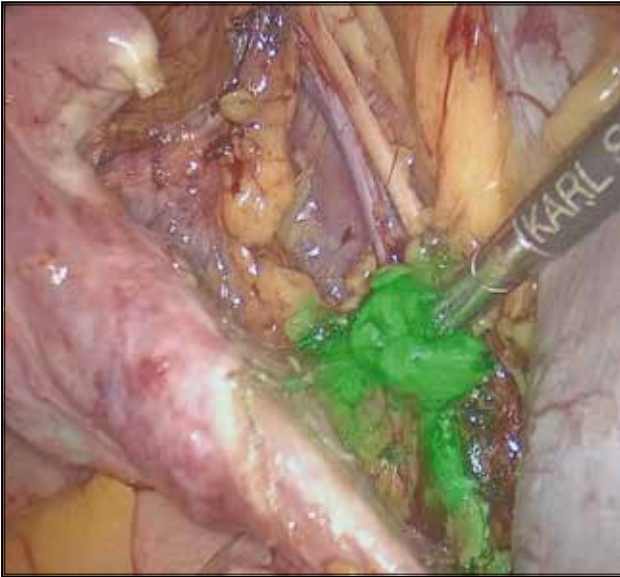


Figure. Laparoscopic sentinel lymph node identification in endometrial cancer with cervical injection of indocyanine green.

to 0.5%)²⁹, but it should be avoided in patients with iodine allergy and hepatic failure because it is metabolised by the liver¹⁷. ICG has an excellent toxicity profile and higher overall and bilateral detection rates, compared with blue dye alone or a combination of Tc-99m and blue dye^{22,30}. The bilateral mapping rate of SLN was significantly higher with ICG than with methylene blue (78% vs 61%) for endometrial cancer and cervical cancer³¹. The complete lymphadenectomy rate secondary to failed mapping was 9% in the ICG group and 28% in the methylene blue group. ICG yielded a higher overall detection rate (95% vs 81%) and higher bilateral detection rate (85% vs 54%) than methylene blue did³². The increase in SLN detection rate reduced the need for complete lymphadenectomy in the ICG group (39% vs 61%, $p < 0.001$)³².

Where to inject?

Uterine corpus injection can be peri-tumoral, subserosal, or myometrial via direct injection, ultrasound guidance or hysteroscopy³³. Deep and superficial injection of ICG at 3 and 9 o'clock or 3, 6, 9, and 12 o'clock of the cervix is the most common method³⁴. The mixture involves 25 mg of ICG powder with 10 to 20 mL of sterile water and 4 to 8 mL of the diluted ICG solution^{33,34}. Cervical injection is easy to master, with high reproducibility and detection rate, as cervical deformation secondary to pathology is much less common, compared with that in the uterine corpus³⁴. The main lymphatic drainage to the uterus is from the parametria. Therefore, a combined superficial (1-3 mm)

and deep (1-2 cm) cervical injection is adequate³⁴. A uterine fundal serosa injection is less favoured because it does not reflect the parametrial lymphatic drainage³⁴, most early endometrial cancer does not invade to the serosal layer, and the injection is commonly affected by anatomical uterine distortion secondary to fibroid. When initial SLNM fails, reinjection with an additional 1 mL of diluted ICG to the superficial cervix of the no SLN detection side can increase the detection rate³⁵.

A meta-analysis reported that all studies with ≥ 100 patients had overall detection rates of $>80\%$, regardless of the injection site³⁶. A systematic review reported an overall detection rate of 62% to 100% after cervical injection, which is higher than the 73% to 95% after uterine corpus injection³⁶. A retrospective study of 221 hysteroscopic injections reported a high overall detection rate of 94.1% and bilateral mapping rate of 62.5%²⁴. However, hysteroscopic injection is more technically demanding than cervical injection, with less reproducible results. A combination of cervical and uterine fundus injection can increase the detection rate, with an overall detection rate being 92.8% for any SLN, 89.2% for pelvic SLN, 61.3% for bilateral SLN, and 4% for isolated para-aortic SLN³⁷.

Although cervical injection has higher overall detection rate of SLN, it has lower para-aortic SLN detection rate than uterine corpus injection. Metastasis to the para-aortic nodes through gonadal vessels and infundibulopelvic ligaments may be missed when cervical injection is used. A systematic review reported that cervical injection has a higher bilateral SLN detection rate (56% vs 33%) but a lower paraaortic SLN detection rate (7% vs 27%, $p = 0.001$), compared with uterine corpus injection³⁰. A meta-analysis reported that para-aortic mapping was most frequent after uterine corpus injection (39%), follow by deep cervical injection (17%) and superficial cervical injection (2%)³⁶. Compared with cervical injection, hysteroscopic injection detects 10% more para-aortic lymph node metastasis and is superior in detecting isolated para-aortic SLN (5.8% vs 0%)³⁸. Bilateral cornu follow by cervical injection increases the upper para-aortic SLN detection rate from 5.7% to 38.2% and the lower para-aortic SLN detection rate from 18.7% to 67.1%, compared with cervical injection only³⁹. The number of metastatic para-aortic SLN detected increases from 2.4% to 7.9% ($p = 0.070$). Cervical injection missed five of eight para-aortic lymph node metastases, but none was missed after cornu plus cervical injection.

ICG should be injected after the induction of anaesthesia. Dissection of the retroperitoneum is

commenced once the injection is completed. It takes a median of 10 minutes to complete SLNM for each pelvis side²⁸. Most SLNs are identified in the external iliac (38% to 50.2%), followed by obturator (25% to 39.8%), infra-mesenteric para-aortic (14%), common iliac (4.8% to 8%), internal iliac (10%), presacral (3%), infrarenal para-aortic (1% to 5.2%), and other sites (1%)^{40,41}.

Sentinel lymph node algorithm

The Memorial Sloan Kettering Cancer Center advocates the implementation of the SLN algorithm when performing SLNM in endometrial cancer⁴². The National Comprehensive Cancer Network recommends adoption of the SLN algorithm to ensure a low false negative rate⁴³. The algorithm involves peritoneal and serosal evaluation and washings, retroperitoneal evaluation including removal of all SLNs and any suspicious nodes, and a side-specific pelvic, common iliac, and interiliac lymph node dissection if there is no mapping in a hemipelvis. A para-aortic lymphadenectomy is left to the attending surgeon's discretion⁴². This approach results in approximately 40% of patients requiring unilateral and 10% requiring bilateral complete lymphadenectomy⁴⁰. The implementation of the algorithm with side-specific lymphadenectomy for mapping failure decreases the false negative rate of SLNM from 14.9% to 1.9% and increases the sensitivity from 85.1% to 98.1%, and NPV from 98.1% to 99.8%⁴². The use of the SLN algorithm in endometrial cancer patients after SLNM revealed a high sensitivity of 95%, NPV of 99%, and low false negative rate of 5%³⁶.

Frozen section of the SLN is generally not performed, owing to its cost, low sensitivity in diagnosing low volume metastasis, and potential alteration to ultrastaging of the SLN¹⁷. Intra-operative frozen section has a low sensitivity of 50% to 83% in identifying lymph node metastasis^{44,45}. The aim of SLN removal is to guide adjuvant therapy, rather than to determine whether complete lymphadenectomy should be performed. If a SLN showed metastasis, adjuvant chemotherapy should be administered to improve survival⁶.

Performance of SLNM

SLNM in endometrial cancer has a high detection rate, high sensitivity, high NPV, and low false negative rate. The FIRES trial with 340 patients receiving SLNM through cervical injection of ICG reported a detection rate of 86%, bilateral detection rate of 52%, sensitivity of 97.2%, NPV of 99.6%, and a false negative rate of 3%⁴⁰. Early-stage low-risk cases comprised 71% of cases, and the positive lymph node rate was 12%⁴⁰. A meta-analysis

involving 4915 patients reported an overall detection rate of SLN of 81% (range, 75.4%-90.4%), bilateral pelvic node detection rate of 50% (range, 33%-74.6%), and paraaortic lymph node detection rate of 17% (range, 6.7%-26.8%)³⁰. The sensitivity was 96%³⁰. When early-stage low-risk endometrial cancer (with low risk of lymph node metastasis) comprises most cases, SLNM is accurate for lymph node assessment and is widely accepted as a routine procedure for staging.

In early-stage high-risk endometrial cancer, the evidence is not as strong, as the number of such cases is relatively small. In the SENTI-ENDO study in 2011 using blue dye with Tc-99m, all three false negative cases among 133 cases occurred in patients with type 2 histology. A retrospective multicentre study in 2015 that included the SENTI-ENDO cohort reported an exceedingly high false negative rate of 20% for high-risk endometrial cancer⁴⁶, raising the concern of the effectiveness of SLNM in high-risk endometrial cancer²¹. The higher risk of lymph node metastasis in high-risk cases also increases the concern of missing a metastatic case, leading to understaging and inappropriate adjuvant treatment, thereby compromising patient survival. Nonetheless, early-stage high-risk endometrial cancer was comparable with low-risk endometrial cancer in terms of sensitivity, NPV, and false negative rate of SLNM. In a prospective study that evaluated 101 patients with high-risk endometrial cancer (grade 3, serous, clear cell, carcinosarcoma) who underwent pelvic and para-aortic lymphadenectomy, the detection rate of SLN per patient was 89%, the bilateral detection rate was 58%, and the sensitivity was 95%⁴⁰. Only one patient had bilateral negative SLN and positive non-SLNs on final pathology (false negative). In a retrospective review of 128 patients with high-risk endometrial cancer (endometrioid grade 3, serous, clear cell, carcinosarcoma, undifferentiated), the overall detection rate was 89.8% for SLN and 63.2% for bilateral SLN, the overall sensitivity was 95.8%, the NPV was 98.2%, and the false negative rate was 4.2%⁴⁷. In the SHREC trial, a prospective study with 257 stage I-II endometrial cancer cases with adherence to the SLN algorithm, the sensitivity and NPV for lymph node involvement was 100%, with a bilateral mapping rate of 95%⁴⁸. The SENTOR study included only early-stage high-grade endometrial cancer; all patients underwent SLNM followed by complete lymphadenectomy, with adherence to the SLN algorithm⁴⁹. Node positive disease was found in 17% of patients; the SLN detection rate per patient was 97.4%, the bilateral detection rate was 77.6%, the sensitivity was 96%, the NPV was 99%, and the false negative rate was 4%. Only one (0.6%) patient was misclassified by the SLN

algorithm. A meta-analysis including 16 studies targeting high-grade endometrial cancer with cervical injection of ICG reported a detection rate of 91% per patient, a bilateral detection rate of 64%, with a sensitivity of 92%, NPV of 97%, and false negative rate of 8%⁵⁰. These studies showed that in high-risk early-stage endometrial cancer, SLNM is also feasible with a high detection rate, sensitivity, NPV, and low false negative rate.

Obesity, surgeon experience, and lymphovascular space invasion decrease the detection rate of SLNM^{36,51-53}. A retrospective study with 472 cases reported that cases with successful and unsuccessful mapping had a median body mass index of 29.8 kg/m² and 34.7 kg/m², respectively⁵³. A meta-analysis reported that all studies with ≥ 100 patients had an overall detection rates of $>80\%$, indicating the importance of surgical experience in achieving a high detection rate³⁶. After the first 30 cases, the rate of successful mapping significantly increased from 77% to 94%⁵². A Korean study reported that at least 27 cases were required to achieve proficiency in SLNM⁵⁴. The learning curve for successful bilateral mapping plateaus at around 40 cases⁵⁵. Before competence in SLNM is achieved, an add-on completion pelvic lymphadenectomy is recommended to avoid missing any lymph node metastasis and to establish the performance and accuracy¹⁷.

Benefit of SLNM

SLNM offers an appropriate balance between morbidity of a complete lymphadenectomy and the risk of missing lymph node metastasis. SLNM is a relatively safe procedure with no adverse events³⁵. Lymphadenectomy is associated with complications such as lymphedema (37%), lymphocele (17%), lymph-ascites, and peripheral nerve injury and vessel injury⁵⁶. The risk of lymphedema correlates with the number of lymph nodes removed, with the risk increasing from $<8\%$ with <5 lymph nodes removed to 30% to 40% with >15 lymph nodes removed⁵⁷. The chance of infected lymphocyst also increases with the increasing number of pelvic lymph nodes removed⁵⁸. SLNM reduces the number of lymph nodes removed, thus reducing the risk of complications. In a study comparing SLNM (n=642, 57%) with complete pelvic and para-aortic lymphadenectomy (n=493, 43%) based on clinical high-risk factors (grade 3 cancer and/or primary tumour diameter >2 cm) in two centres, the median number of lymph nodes removed was six in the SLNM group and 34 in the complete lymphadenectomy group, whereas the median number of para-aortic lymph nodes removed was 5 and 16, respectively⁵⁹. SLN removal alone resulted in a lower incidence of leg lymphedema than complete

pelvic and paraaortic lymphadenectomy (1.3% vs 18.1%, $p=0.0003$)⁶⁰. In a retrospective review of 348 patients, lymphocele was found in 3.4% (n=6/178) of SLNM-only patients, compared with 14.1% (n=24/170) in the SLNM with complete lymphadenectomy group ($p=0.009$)⁶¹. Complete lymphadenectomy was the only risk factor for lymphocele in a multivariate analysis (odds ratio=3.68, $p=0.009$)⁶¹. The operative time (244 min vs 140 min), blood loss (240 mL vs 94 mL), length of hospital stay, and postoperative complication were lower in the SLN removal group than in the complete lymphadenectomy group^{16,62}. A before and after study reported that adoption of SLNM decreased the mean number of pelvic lymph nodes removed (15 vs 4, $p<0.0001$), the mean operative time (181 min vs 137 min, $p<0.0001$), the estimated blood loss (80 mL vs 56 mL, $p=0.004$), and the rate of postoperative complications (13% vs 5.2%, $p=0.04$)⁶³. The mean additional operative time for removal of SLN was 33 min; 91 min were saved compared with a complete pelvic and paraaortic lymphadenectomy⁶⁰. A retrospective review of 154 endometrial cancer patients with 109 SLNM procedures reported that the adoption of SLNM spared 26 pelvic and para-aortic lymphadenectomy⁶⁴. SLNM minimised surgical risk without compromising oncological safety, thereby improving the quality of life of patients.

SLNM increases the identification of lymph node metastatic disease, with a lower number of lymph nodes removed when compared with complete lymphadenectomy^{65,66}. SLNM allows more accurate assessment of the lymph nodes status in endometrial cancer. An increase detection of lymph node involvement with SLNM is associated with an increase in detection of stage IIIC disease. In the FIRES trial, 17% of the positive SLN were found in regions outside the routine lymphadenectomy area (eg pre-sacral area) and would have been missed if SLNM was not performed⁴⁰. Similarly, in the SENTOR trial, 26% of node positive cases were outside routine lymphadenectomy boundaries or required immunohistochemistry (IHC) for diagnosis⁴⁹. More stage IIIC1 disease were identified in the SLNM group than the complete lymphadenectomy group (16.7% vs 7.3%)⁶⁶. Comparing 661 endometrial cancer cases with pelvic +/- para-aortic lymphadenectomy with 119 endometrial cancer cases with SLNM + pelvic +/- para-aortic lymphadenectomy, the SLNM group had more lymph node metastasis detected (30.3% vs 14.7%, $p<0.001$), more stage IIIC (30.2% vs 14.5%, $p<0.001$), and received more chemotherapy + radiation (28.6% vs 16.3%, $p<0.003$)⁶⁵. The SLN was the only metastasis in 50% of SLNM cases with positive nodes, and the SLN false negative rate was

1/36 (2.8%)⁶⁵. In a retrospective study on high-risk early-stage endometrial cancer, the SLNM group had more pelvic node metastases detected than the non-SLNM group (pelvic +/- para-aortic lymphadenectomy) [26.7% vs 14.3%, $p=0.02$] and received more adjuvant chemotherapy (48% vs 33.5%, $p=0.03$)⁶⁷. In meta-analysis including 1249 (35.3%) patients with SLNM and 2287 (64.7%) patients with complete lymphadenectomy, positive pelvic nodes were detected in 184/1249 (14.7%) patients with SLNM and 228/2287 (9.9%) patients with complete lymphadenectomy (odds ratio=2.03, $p=0.002$). No difference in detection of positive nodes located in the paraaortic region was observed (odds ratio=0.93)⁶⁸. SLN biopsy upstaged 10% of patients with low risk and 15% of those with intermediate risk endometrial cancer²¹. Patients staged with SLNM were more likely to receive adjuvant treatment^{30,65}, because of the higher detection rate of metastatic disease. These data indicate that SLNM is more accurate in identifying lymph node metastasis and provides better guidance to adjuvant therapy. The higher detection rate is partly due to ultrastaging. SLNM can identify lymph nodes at particular high risk of metastasis, allowing pathologist to concentrate on these smaller number of more relevant lymph nodes with ultrastaging.

Ultrastaging and low volume metastasis

Ultrastaging is a pathological technique to increase the accuracy of lymph node assessment. In the SENTOR study, 26% of node-positive cancer were identified outside traditional pelvic lymph node boundaries or required IHC for diagnosis⁴⁹. Initial pathological examination only detects half of the lymph node metastasis, whereas ultrastaging detects the other half in the form of low volume metastasis^{24,40}. There is no standardised protocol for ultrastaging and various protocols have been reported⁶⁹. More comprehensive and exhaustive protocols do not appear to be superior in comparative studies^{69,70}. In essence, it involves performing more serial sections of the negative SLN and the use of IHC for cytokeratin rather than only haematoxylin and eosin (H&E) staining. In the FIRES trial, SLN were cut at 3-mm intervals, in a bread loaf fashion, or bivalved if <1.5 cm. Two paraffin embedded slides were created from each section, 50 μ m apart. One slide was stained for H&E and the other for IHC if no metastatic disease was found on the H&E slide⁴⁰. Ultrastaging picks up low volume metastasis, which is not detected by routine histology, thereby increasing detection of lymph node metastasis. Similar to axillary SLN of breast cancers, macrometastasis is defined as foci of metastasis of >2 mm. Low volume metastasis includes micrometastasis, which is defined as metastasis of 0.2-2 mm, and isolated

tumour cells (ITC), which is defined as foci of metastasis <0.2 mm or cells stained positive for cytokeratins⁴⁰. IHC and serial sectioning were shown to detect metastases undiagnosed by conventional histology in 8% patients with detected SLN, representing 47% of metastases²¹. In a retrospective study with 26 lymph node metastases identified, 46.2% were macrometastases, 23.1% were micrometastases, and 30.7% were ITCs²⁴. In the FIRES trial, 54% of positive lymph nodes are micrometastasis or ITC⁴⁰. Among the low volume metastasis cases, 47% were micrometastases and 53% were ITCs. In high-risk early-stage endometrial cancers, 40% of positive SLN were detected only after IHC⁶⁷. The risk of ITC increases with depth of myometrial invasion: 25% for deeply invasive grade 1/2 and 18% for deeply invasive grade 3 tumours⁷¹. The clinical implications of micrometastasis and ITC are yet to be determined. Excellent prognosis of ITC patients after receiving adjuvant therapy was demonstrated: the PFS at 3 years was 95.5%, similar to node negative patients (87.6%) and micrometastasis patients (85.5%), and better than patients with macrometastasis (58.5%)⁷². The survival rate was comparable between those with node negative disease and those with micrometastasis treated with adjuvant chemotherapy, but the survival rate was worse for those with micrometastasis without adjuvant therapy⁷³. This supports the need of adjuvant therapy for micrometastasis. However, the benefit of adjuvant therapy for ITC is not proven. ITC is not considered as stage IIIC disease but should be noted on staging. The National Comprehensive Cancer Network recommends to designate ITC as stage pN0 (i+)⁴³. In a world-wide survey of gynae-oncologists in 2019, 52% recommended adjuvant therapy if micrometastases were detected, but only 13.8% recommended adjuvant therapy for ITC¹⁰. Further studies are required to clarify the impact of low volume metastasis on prognosis and whether adjuvant therapy should be given.

Oncological safety of SLNM

The decrease in radicality of surgery with SLNM does not compromise oncological safety in terms of OS and PFS^{66,74,75}. The long-term results of the SENTI-ENDO study with a median follow-up of 50 months and 14.4% rate of recurrence, the 50 months recurrence-free survival (RFS) was 84.7%, with no difference between patients with and without detected SLN ($p=0.09$)⁷⁶. In 802 patients with preoperative stage 1 endometrial cancer, positive pelvic lymph nodes were found in 16.7% of patients who underwent surgical staging by SLNM +/- complete lymphadenectomy and in 7.3% of patients who underwent complete lymphadenectomy ($p=0.002$)⁶⁶. Three-year

disease-free survival was 90.4% in the SLNM group and 89.6% in the complete lymphadenectomy group.

No difference in survival was found in patients with uterine serous carcinoma undergoing SLNM alone versus complete lymphadenectomy. In a retrospective study involving 245 cases with 60.1% of stage I or II cases, the 2-year OS was 96.6% in the SLNM and 89.6% in the complete lymphadenectomy group ($p=0.8$), whereas the 2-year OS in those with stage III disease was 73.6% in the SLNM group and 77.3% in the complete lymphadenectomy group ($p=0.8$)⁷⁷.

In a multi-institutional retrospective study evaluating long-term outcomes (≥ 3 years) of endometrial cancer patients who underwent (1) complete lymphadenectomy, (2) SLNM followed by lymphadenectomy, or (3) SLNM alone, the three groups were comparable in terms of DFS and OS⁷⁸. The treatment strategies did not affect survival outcomes after stratification into low-, intermediate-, and high-risk patients.

In addition, the recurrence rate was comparable after SLNM or complete lymphadenectomy. In a retrospective study with 279 patients (103 with no lymphadenectomy, 118 with SLN removal, 59 with pelvic +/- para-aortic lymphadenectomy), the risk of recurrence was comparable after complete lymphadenectomy or SLN removal⁵⁹. In a meta-analysis including 1249 (35.3%) patients with SLNM and 2287 (64.7%) patients with lymphadenectomy, the overall recurrence rate was 4.3% and 7.3%, and the nodal recurrence rate was 1.2% and 1.7%, respectively⁶⁸.

Some studies reported an improvement in survival with SLNM. In a retrospective study with 472 consecutive patients with endometrial cancer who underwent either SLNM and complete lymphadenectomy ($n=275$) or complete lymphadenectomy ($n=197$) from sequential, non-overlapping historical time points, there was no significant difference in overall RFS between the two groups at 48 months⁷⁹. Patients with SLNM and complete lymphadenectomy had a reduced recurrence rate in the pelvic sidewall (30% vs 71.4%) and thus improved RFS (hazard ratio=0.32)⁷⁹. Similarly, in a study with 193 patients with complete lymphadenectomy and 250 patients with SLNM and completion lymphadenectomy after a median follow-up period of 6.9 years, the addition of SLNM was associated with improved 6-year OS (90% vs 81%, $p=0.009$), improved 6-year PFS (85% vs 75%, $p=0.01$), and improved 6-year RFS (95% vs 90%, $p=0.04$)⁸⁰. This

improvement in survival may be due to the more accurate lymph node assessment by SLNM and ultrastaging, thus allowing more accurate provision of adjuvant therapy.

The comparison on oncological safety is hindered and complicated by the fact that only a small number of studies compared SLNM only with complete lymphadenectomy, while most studies compared SLNM and completion lymphadenectomy with complete lymphadenectomy only, particularly for high-risk early-stage endometrial cancer. Moreover, para-aortic lymphadenectomy is not performed in many of the studies. The survival comparison is also affected by the imbalance of adjuvant therapy given and the lack of prospective study and long-term follow-up. Nonetheless, studies are supportive of SLNM, with a similar survival rate but lower morbidity. Both the International Federation of Gynecology and Obstetrics and the National Comprehensive Cancer Network supported the use of SLNM with adherence to the SLN algorithm in early-stage endometrial cancer³³ and in high-risk early-stage endometrial cancer⁸¹, although 66% of gynae-oncological surgeons among 69 countries self-reported to perform a backup lymphadenectomy in high-risk patients¹⁰.

Non-SLN metastasis

There are concerns over non-SLN metastasis that are not removed when the SLN algorithm is adopted. In a study with 268 endometrial cancer treated with SLNM and lymphadenectomy, 16% of patients were found to have SLN metastasis, and non-SLN metastases were found in 34.8% of patients with positive SLN⁸². In cases of low volume metastasis, the risk of having another positive lymph node was only 5%⁸². A prospective study with 200 cases reported a 40% rate of non-SLN metastasis⁸³. Lymph nodes should be inspected carefully intra-operatively, and strict adherence to the SLN algorithm with removal of macroscopically suspicious lymph nodes should be performed. Theoretically, non-macroscopic metastasis can be controlled with adjuvant therapy⁶. A retrospective study comparing SLNM only with SLNM plus backup lymphadenectomy reported that backup lymphadenectomy removed 11% non-SLN metastasis but had no impact on survival⁸⁴. However, further studies are required to clarify the optimal strategy to tackle non-SLN metastasis. The role of repeat surgery to remove the remaining lymph nodes that are not macroscopically involved is doubtful, because adjuvant chemotherapy can treat the non-SLN metastasis and repeat surgery carries surgical risk and delays chemotherapy administration.

Para-aortic lymph node disease

The SLN algorithm leaves the decision of whether to perform para-aortic lymphadenectomy to the surgeons' discretion. The risk of para-aortic metastasis is as high as 51% in the presence of pelvic lymph node metastasis⁸⁵. In cases where pelvic SLN is positive but para-aortic lymphadenectomy has not been performed, adjuvant chemotherapy for positive pelvic SLN can theoretically treat the microscopic para-aortic metastasis, assuming macroscopic para-aortic metastasis has been removed according to the SLN algorithm. However, the SLN algorithm can miss the rare occurrence of isolated para-aortic metastasis, in which the para-aortic lymph nodes are positive when the pelvic lymph nodes are negative for metastasis³⁴. In the MSKCC data when SLNM is a routine procedure for both low-risk and high-risk early-stage endometrial cancer, only one among 498 patients had an isolated positive right paraaortic lymph node with a negative ipsilateral SLN and pelvic lymphadenectomy⁴². In the FIRES trial with 66% of low-risk stage 1A endometrial cancer, isolated para-aortic metastases were reported in 0.5% of cases⁴⁰. Even in high-risk endometrial cancer with higher risk of lymph node metastasis, the SHREC trial reported isolated para-aortic metastases in only 1% of patients⁴⁸. A literature review reported a 1.5% incidence of isolated para-aortic lymph node metastasis in endometrial cancer⁸⁶. Failure to identify para-aortic metastasis in a negative pelvic lymph node patient may lead to the failure to administer appropriate adjuvant therapy. SLNM can increase the detection rate of pelvic lymph node

metastasis by ultrastaging and can decrease the prevalence of isolated para-aortic metastases⁸⁷. In a study with 236 high-risk cases, 3.5% in the non-SLN group had isolated para-aortic node metastases versus none in the SLNM group⁶⁷. However, the sensitivity, NPV, and false negative rate of SLNM for para-aortic disease were not described. Preoperative imaging and para-aortic lymphadenectomy based on clinical risk factors should be performed to mitigate the problem of isolated para-aortic metastasis. Para-aortic lymphadenectomy should be performed in cases of macroscopically enlarged lymph nodes, high-risk histology, deep myometrial invasion, and suspicious nodes on imaging¹⁷.

Conclusion

SLNM with adherence to the SLN algorithm provides an effective option for lymph node assessment in endometrial cancer, balancing the morbidity of complete lymphadenectomy with the risk of missing lymph node involvement. SLNM is considered a routine practice in low-risk early-stage endometrial cancer, allowing accurate staging while decreasing morbidity. Recent evidence suggests similar staging performance in high-risk early-stage endometrial cancer, making SLNM a reasonable alternative in high-risk endometrial cancer. Further prospective studies with long-term follow-up comparing SLNM only with complete lymphadenectomy in high-risk endometrial cancer are required. The role of para-aortic lymphadenectomy and optimal therapy for low volume metastasis also warrant further investigations.

References

1. Siegel RL, Miller KD, Fuchs HE, Jemal A. Cancer Statistics, 2021. *CA Cancer J Clin* 2021;71:7-33. [Crossref](#)
2. Hong Kong Cancer Registry. Available from: <https://www3.ha.org.hk/cancereg/>. Assessed 16 April 2022.
3. Rungruang B, Olawaiye AB. Comprehensive surgical staging for endometrial cancer. *Rev Obstet Gynecol* 2012;5:28-34.
4. Pecorelli S. Revised FIGO staging for carcinoma of the vulva, cervix, and endometrium. *Int J Gynaecol Obstet* 2009;105:103-4. [Crossref](#)
5. Randall ME, Filiaci VL, Muss H, et al. Randomized phase III trial of whole-abdominal irradiation versus doxorubicin and cisplatin chemotherapy in advanced endometrial carcinoma: a Gynecologic Oncology Group Study. *J Clin Oncol* 2006;24:36-44. [Crossref](#)
6. de Boer SM, Powell ME, Mileschkin L, et al. Adjuvant chemoradiotherapy versus radiotherapy alone for women with high-risk endometrial cancer (PORTEC-3): final results of an international, open-label, multicentre, randomised, phase 3 trial. *Lancet Oncol* 2018;19:295-309. [Crossref](#)
7. Cetinkaya K, Atalay F, Bacinoglu A, et al. To what extent is risk grouping method successful in deciding surgical staging in endometrial cancer? *Tumori* 2016;102:422-5. [Crossref](#)
8. Mariani A, Webb MJ, Keeney GL, et al. Low-risk corpus cancer: is lymphadenectomy or radiotherapy necessary? *Am J Obstet Gynecol* 2000;182:1506-19. [Crossref](#)
9. Renz M, Diver E, English D, et al. Sentinel lymph node biopsies in endometrial cancer: practice patterns among gynecologic oncologists in the United States. *J Minim Invasive Gynecol* 2020;27:482-8. [Crossref](#)
10. Casarin J, Multinu F, Abu-Rustum N, et al. Factors influencing the adoption of the sentinel lymph node technique for endometrial cancer staging: an international survey of gynecologic oncologists. *Int J Gynecol Cancer* 2019;29:60-7. [Crossref](#)

11. Todo Y, Kato H, Kaneuchi M, et al. Survival effect of para-aortic lymphadenectomy in endometrial cancer (SEPAL study): a retrospective cohort analysis. *Lancet* 2010;375:1165-72. [Crossref](#)
12. Trimble EL, Kosary C, Park RC. Lymph node sampling and survival in endometrial cancer. *Gynecol Oncol* 1998;71:340-3. [Crossref](#)
13. Kilgore LC, Partridge EE, Alvarez RD, et al. Adenocarcinoma of the endometrium: survival comparisons of patients with and without pelvic node sampling. *Gynecol Oncol* 1995;56:29-33. [Crossref](#)
14. ASTEC study group; Kitchener H, Swart AM, Qian Q, Amos C, Parmar MK. Efficacy of systematic pelvic lymphadenectomy in endometrial cancer (MRC ASTEC trial): a randomised study. *Lancet* 2009;373:125-36. [Crossref](#)
15. Benedetti Panici P, Basile S, Maneschi F, et al. Systematic pelvic lymphadenectomy vs. no lymphadenectomy in early-stage endometrial carcinoma: randomized clinical trial. *J Natl Cancer Inst* 2008;100:1707-16. [Crossref](#)
16. Dowdy SC, Borah BJ, Bakkum-Gamez JN, et al. Prospective assessment of survival, morbidity, and cost associated with lymphadenectomy in low-risk endometrial cancer. *Gynecol Oncol* 2012;127:5-10. [Crossref](#)
17. Holloway RW, Abu-Rustum NR, Backes FJ, et al. Sentinel lymph node mapping and staging in endometrial cancer: a Society of Gynecologic Oncology literature review with consensus recommendations. *Gynecol Oncol* 2017;146:405-15. [Crossref](#)
18. Frumovitz M, Slomovitz BM, Singh DK, et al. Frozen section analyses as predictors of lymphatic spread in patients with early-stage uterine cancer. *J Am Coll Surg* 2004;199:388-93. [Crossref](#)
19. Antonsen SL, Jensen LN, Loft A, et al. MRI, PET/CT and ultrasound in the preoperative staging of endometrial cancer: a multicenter prospective comparative study. *Gynecol Oncol* 2013;128:300-8. [Crossref](#)
20. Burke TW, Levenback C, Tornos C, et al. Intraabdominal lymphatic mapping to direct selective pelvic and paraaortic lymphadenectomy in women with high-risk endometrial cancer: results of a pilot study. *Gynecol Oncol* 1996;62:169-73. [Crossref](#)
21. Ballester M, Dubernard G, Lécure F, et al. Detection rate and diagnostic accuracy of sentinel-node biopsy in early stage endometrial cancer: a prospective multicentre study (SENTI-ENDO). *Lancet Oncol* 2011;12:469-76. [Crossref](#)
22. Papadia A, Gasparri ML, Buda A, et al. Sentinel lymph node mapping in endometrial cancer: comparison of fluorescence dye with traditional radiocolloid and blue. *J Cancer Res Clin Oncol* 2017;143:2039-48. [Crossref](#)
23. Du J, Li Y, Wang Q, et al. Sentinel lymph node mapping in gynecological oncology. *Oncol Lett* 2017;14:7669-75. [Crossref](#)
24. Martinelli F, Ditto A, Bogani G, et al. Sentinel lymph node mapping in endometrial cancer: performance of hysteroscopic injection of tracers. *Int J Gynecol Cancer* 2020;30:332-8. [Crossref](#)
25. Buda A, Papadia A, Zapardiel I, et al. From conventional radiotracer Tc-99(m) with blue dye to indocyanine green fluorescence: a comparison of methods towards optimization of sentinel lymph node mapping in early stage cervical cancer for a laparoscopic approach. *Ann Surg Oncol* 2016;23:2959-65. [Crossref](#)
26. Cabrera S, Barahona-Orpinell M, Almansa-González C, et al. Combined use of ICG and technetium does not improve sentinel lymph node detection in endometrial cancer: results of the COMBITEC study. *Gynecol Oncol* 2021;162:32-7. [Crossref](#)
27. Thevarajah S, Huston TL, Simmons RM. A comparison of the adverse reactions associated with isosulfan blue versus methylene blue dye in sentinel lymph node biopsy for breast cancer. *Am J Surg* 2005;189:236-9. [Crossref](#)
28. Rozenholc A, Samouelian V, Warkus T, et al. Green versus blue: randomized controlled trial comparing indocyanine green with methylene blue for sentinel lymph node detection in endometrial cancer. *Gynecol Oncol* 2019;153:500-4. [Crossref](#)
29. Papadia A, Gasparri ML, Radan AP, Stämpfli CAL, Rau TT, Mueller MD. Retrospective validation of the laparoscopic ICG SLN mapping in patients with grade 3 endometrial cancer. *J Cancer Res Clin Oncol* 2018;144:1385-93. [Crossref](#)
30. Bodurtha Smith AJ, Fader AN, Tanner EJ. Sentinel lymph node assessment in endometrial cancer: a systematic review and meta-analysis. *Am J Obstet Gynecol* 2017;216:459-76. [e10. Crossref](#)
31. Pölcher M, Matz S, Braun M, Brambs C, Beer M, Hamann M. Sentinel lymph node mapping with indocyanine green compared to blue dye tracer in gynecologic malignancies: a single center experience of 218 patients. *J Surg Oncol* 2021;123:1092-8. [Crossref](#)
32. Eriksson AG, Beavis A, Soslow RA, et al. A comparison of the detection of sentinel lymph nodes using indocyanine green and near-infrared fluorescence imaging versus blue dye during robotic surgery in uterine cancer. *Int J Gynecol Cancer* 2017;27:743-7. [Crossref](#)
33. Zhai L, Zhang X, Cui M, et al. Sentinel lymph node mapping in endometrial cancer: a comprehensive review. *Front Oncol* 2021;11:701758. [Crossref](#)
34. Abu-Rustum NR. Sentinel lymph node mapping for endometrial cancer: a modern approach to surgical staging. *J Natl Compr Canc Netw* 2014;12:288-97. [Crossref](#)
35. Capozzi VA, Valentina C, Giulio S, et al. Sentinel node mapping in endometrial cancer: tips and tricks to improve bilateral detection rate. The sentitricks study, a monocentric experience. *Taiwan J Obstet Gynecol* 2021;60:31-5. [Crossref](#)
36. Cormier B, Rozenholc AT, Gotlieb W, et al. Sentinel lymph node procedure in endometrial cancer: a systematic review and proposal for standardization of future research. *Gynecol Oncol* 2015;138:478-85. [Crossref](#)
37. Ruiz R, Gorostidi M, Jaunarena I, et al. Sentinel node biopsy in endometrial cancer with dual cervical and fundal indocyanine green injection. *Int J Gynecol Cancer* 2018;28:139-44. [Crossref](#)
38. Ditto A, Casarin I, Pinelli C, et al. Hysteroscopic versus cervical injection for sentinel node detection in endometrial cancer: a multicenter prospective randomised controlled trial from the Multicenter Italian Trials in Ovarian cancer (MITO) study group. *Eur J Cancer* 2020;140:1-10. [Crossref](#)

39. Kim YN, Eoh KJ, Lee JY, et al. Comparison of outcomes between the one-step and two-step sentinel lymph node mapping techniques in endometrial cancer. *Int J Gynecol Cancer* 2020;30:318-24. [Crossref](#)
40. Rossi EC, Kowalski LD, Scalici J, et al. A comparison of sentinel lymph node biopsy to lymphadenectomy for endometrial cancer staging (FIRES trial): a multicentre, prospective, cohort study. *Lancet Oncol* 2017;18:384-92. [Crossref](#)
41. Soliman PT, Westin SN, Dioun S, et al. A prospective validation study of sentinel lymph node mapping for high-risk endometrial cancer. *Gynecol Oncol* 2017;146:234-9. [Crossref](#)
42. Barlin JN, Khoury-Collado F, Kim CH, et al. The importance of applying a sentinel lymph node mapping algorithm in endometrial cancer staging: beyond removal of blue nodes. *Gynecol Oncol* 2012;125:531-5. [Crossref](#)
43. Uterine Neoplasms, Version 1.2021, NCCN Clinical Practice Guidelines in Oncology.
44. Bellaminutti S, Bonollo M, Gasparri ML, et al. Sentinel lymph node intraoperative analysis in endometrial cancer. *J Cancer Res Clin Oncol* 2020;146:3199-205. [Crossref](#)
45. Renz M, Marjon N, Devereaux K, et al. Immediate intraoperative sentinel lymph node analysis by frozen section is predictive of lymph node metastasis in endometrial cancer. *J Robot Surg* 2020;14:35-40. [Crossref](#)
46. Naoura I, Canlorbe G, Bendifallah S, et al. Relevance of sentinel lymph node procedure for patients with high-risk endometrial cancer. *Gynecol Oncol* 2015;136:60-4. [Crossref](#)
47. Touhami O, Grégoire J, Renaud MC, et al. Performance of sentinel lymph node (SLN) mapping in high-risk endometrial cancer. *Gynecol Oncol* 2017;147:549-53. [Crossref](#)
48. Persson J, Salehi S, Bollino M, Lönnerfors C, Falconer H, Geppert B. Pelvic sentinel lymph node detection in high-risk endometrial cancer (SHREC-trial)-the final step towards a paradigm shift in surgical staging. *Eur J Cancer* 2019;116:77-85. [Crossref](#)
49. Cusimano MC, Vicus D, Pulman K, et al. Assessment of sentinel lymph node biopsy vs lymphadenectomy for intermediate- and high-grade endometrial cancer staging. *JAMA Surg* 2021;156:157-64. [Crossref](#)
50. Marchocki Z, Cusimano MC, Clarfield L, et al. Sentinel lymph node biopsy in high-grade endometrial cancer: a systematic review and meta-analysis of performance characteristics. *Am J Obstet Gynecol* 2021;225:367.e1-367.e39. [Crossref](#)
51. Eriksson AG, Montovano M, Beavis A, et al. Impact of obesity on sentinel lymph node mapping in patients with newly diagnosed uterine cancer undergoing robotic surgery. *Ann Surg Oncol* 2016;23:2522-8. [Crossref](#)
52. Khoury-Collado F, Glaser GE, Zivanovic O, et al. Improving sentinel lymph node detection rates in endometrial cancer: how many cases are needed? *Gynecol Oncol* 2009;115:453-5. [Crossref](#)
53. Eitan R, Sabah G, Krissi H, et al. Robotic blue-dye sentinel lymph node detection for endometrial cancer - Factors predicting successful mapping. *Eur J Surg Oncol* 2015;41:1659-63. [Crossref](#)
54. Kim S, Ryu KJ, Min KJ, et al. Learning curve for sentinel lymph node mapping in gynecologic malignancies. *J Surg Oncol* 2020;121:599-604. [Crossref](#)
55. Tucker K, Staley SA, Gehrig PA, et al. Defining the learning curve for successful staging with sentinel lymph node biopsy for endometrial cancer among surgeons at an academic institution. *Int J Gynecol Cancer* 2020;30:346-51. [Crossref](#)
56. Volpi L, Sozzi G, Capozzi VA, et al. Long term complications following pelvic and para-aortic lymphadenectomy for endometrial cancer, incidence and potential risk factors: a single institution experience. *Int J Gynecol Cancer* 2019;29:312-9. [Crossref](#)
57. Beesley VL, Rowlands IJ, Hayes SC, et al, Australian National Endometrial Cancer Study Group. Incidence, risk factors and estimates of a woman's risk of developing secondary lower limb lymphedema and lymphedema-specific supportive care needs in women treated for endometrial cancer. *Gynecol Oncol* 2015;136:87-93. [Crossref](#)
58. Ma X, Wang Y, Fan A, et al. Risk factors, microbiology and management of infected lymphocyst after lymphadenectomy for gynecologic malignancies. *Arch Gynecol Obstet* 2018;298:1195-203. [Crossref](#)
59. Zahl Eriksson AG, Ducie J, Ali N, et al. Comparison of a sentinel lymph node and a selective lymphadenectomy algorithm in patients with endometrioid endometrial carcinoma and limited myometrial invasion. *Gynecol Oncol* 2016;140:394-9. [Crossref](#)
60. Geppert B, Lönnerfors C, Bollino M, et al. Sentinel lymph node biopsy in endometrial cancer-Feasibility, safety and lymphatic complications. *Gynecol Oncol* 2018;148:491-8. [Crossref](#)
61. Diniz TP, Drizlionoks E, Faloppa CC, et al. Impact of sentinel node mapping in decreasing the risk of lymphocele in endometrial cancer. *Ann Surg Oncol* 2021;28:3293-9. [Crossref](#)
62. Imboden S, Mereu L, Siegenthaler F, et al. Oncological safety and perioperative morbidity in low-risk endometrial cancer with sentinel lymph-node dissection. *Eur J Surg Oncol* 2019;45:1638-43. [Crossref](#)
63. Liu CY, Elias KM, Howitt BE, et al. Sentinel lymph node mapping reduces practice pattern variations in surgical staging for endometrial adenocarcinoma: a before and after study. *Gynecol Oncol* 2017;145:248-255. [Crossref](#)
64. Brugger S, Hamann M, Mosner M, et al. Endometrial cancer-how many patients could benefit from sentinel lymph node dissection? *World J Surg Oncol* 2018;16:95. [Crossref](#)
65. Holloway RW, Gupta S, Stavitzski NM, et al. Sentinel lymph node mapping with staging lymphadenectomy for patients with endometrial cancer increases the detection of metastasis. *Gynecol Oncol* 2016;141:206-10. [Crossref](#)
66. Buda A, Di Martino G, Restaino S, et al. The impact on survival of two different staging strategies in apparent early stage endometrial cancer comparing sentinel lymph nodes mapping algorithm and selective lymphadenectomy: an Italian retrospective analysis of two reference centers. *Gynecol Oncol* 2017;147:528-34. [Crossref](#)
67. Baiocchi G, Mantoan H, Kumagai LY, et al. The impact of sentinel node-mapping in staging high-risk endometrial cancer. *Ann Surg Oncol* 2017;24:3981-7. [Crossref](#)

68. Bogani G, Murgia F, Ditto A, et al. Sentinel node mapping vs. lymphadenectomy in endometrial cancer: a systematic review and meta-analysis. *Gynecol Oncol* 2019;153:676-83. [Crossref](#)
69. Euscher E, Sui D, Soliman P, et al. Ultrastaging of sentinel lymph nodes in endometrial carcinoma according to use of 2 different methods. *Int J Gynecol Pathol* 2018;37:242-51. [Crossref](#)
70. Grassi T, Dell'Orto F, Jaconi M, et al. Two ultrastaging protocols for the detection of lymph node metastases in early-stage cervical and endometrial cancers. *Int J Gynecol Cancer* 2020;30:1404-10. [Crossref](#)
71. Mueller JJ, Pedra Nobre S, Braxton K, et al. Incidence of pelvic lymph node metastasis using modern FIGO staging and sentinel lymph node mapping with ultrastaging in surgically staged patients with endometrioid and serous endometrial carcinoma. *Gynecol Oncol* 2020;157:619-23. [Crossref](#)
72. Plante M, Stanleigh J, Renaud MC, et al. Isolated tumor cells identified by sentinel lymph node mapping in endometrial cancer: does adjuvant treatment matter? *Gynecol Oncol* 2017;146:240-6. [Crossref](#)
73. Ignatov A, Lebius C, Ignatov T, et al. Lymph node micrometastases and outcome of endometrial cancer. *Gynecol Oncol* 2019;154:475-9. [Crossref](#)
74. Tschernichovsky R, Diver EJ, Schorge JO, et al. The role of lymphadenectomy versus sentinel lymph node biopsy in early-stage endometrial cancer: a review of the literature. *Am J Clin Oncol* 2016;39:516-21. [Crossref](#)
75. Raimond E, Ballester M, Hudry D, et al. Impact of sentinel lymph node biopsy on the therapeutic management of early-stage endometrial cancer: results of a retrospective multicenter study. *Gynecol Oncol* 2014;133:506-11. [24642092 Crossref](#)
76. Darai E, Dubernard G, Bats AS, et al. Sentinel node biopsy for the management of early stage endometrial cancer: long-term results of the SENTI-ENDO study. *Gynecol Oncol* 2015;136:54-9. [Crossref](#)
77. Basaran D, Bruce S, Aviki EM, et al. Sentinel lymph node mapping alone compared to more extensive lymphadenectomy in patients with uterine serous carcinoma. *Gynecol Oncol* 2020;156:70-6. [Crossref](#)
78. Bogani G, Casarin J, Leone Roberti Maggiore U, et al. Survival outcomes in endometrial cancer patients having lymphadenectomy, sentinel node mapping followed by lymphadenectomy and sentinel node mapping alone: long-term results of a propensity-matched analysis. *Gynecol Oncol* 2020;158:77-83. [Crossref](#)
79. How J, Gauthier C, Abitbol J, et al. Impact of sentinel lymph node mapping on recurrence patterns in endometrial cancer. *Gynecol Oncol* 2017;144:503-9. [Crossref](#)
80. Kogan L, Matanes E, Wissing M, et al. The added value of sentinel node mapping in endometrial cancer. *Gynecol Oncol* 2020;158:84-91. [Crossref](#)
81. Koh WJ, Abu-Rustum NR, Bean S, et al. Uterine Neoplasms, Version 1.2018, NCCN Clinical Practice Guidelines in Oncology. *J Natl Compr Canc Netw* 2018;16:170-99. [Crossref](#)
82. Touhami O, Trinh XB, Gregoire J, et al. Predictors of non-sentinel lymph node (non-SLN) metastasis in patients with sentinel lymph node (SLN) metastasis in endometrial cancer. *Gynecol Oncol* 2015;138:41-5. [Crossref](#)
83. Holloway RW, Ahmad S, Kendrick JE, et al. A prospective cohort study comparing colorimetric and fluorescent imaging for sentinel lymph node mapping in endometrial cancer. *Ann Surg Oncol* 2017;24:1972-9. [Crossref](#)
84. Bogani G, Papadia A, Buda A, et al. Sentinel node mapping vs. sentinel node mapping plus back-up lymphadenectomy in high-risk endometrial cancer patients: results from a multi-institutional study. *Gynecol Oncol* 2021;161:122-9. [Crossref](#)
85. Kumar S, Podratz KC, Bakkum-Gamez JN, et al. Prospective assessment of the prevalence of pelvic, paraaortic and high paraaortic lymph node metastasis in endometrial cancer. *Gynecol Oncol* 2014;132:38-43. [Crossref](#)
86. Chiang AJ, Yu KJ, Chao KC, Teng NN. The incidence of isolated para-aortic nodal metastasis in completely staged endometrial cancer patients. *Gynecol Oncol* 2011;121:122-5. [Crossref](#)
87. Multinu F, Casarin J, Cappuccio S, et al. Ultrastaging of negative pelvic lymph nodes to decrease the true prevalence of isolated paraaortic dissemination in endometrial cancer. *Gynecol Oncol* 2019;154:60-4. [Crossref](#)